

VISUALIZING KEY COMPLICATIONS AT EVERY AGE^{1,2}

Anticipation of potential complications may help optimize patient care during each stage of life

	INFANTS	TODDLERS	CHILDREN	TEENAGERS	ADULTS
FORAMEN MAGNUM STENOSIS*	→				
SLEEP-DISORDERED BREATHING	→				
OTITIS MEDIA	→				
GENU VARUM		→			
SYMPTOMATIC SPINAL STENOSIS			→		
CHRONIC PAIN			→		
LUMBAR HYPERLORDOSIS			→		
DENTAL ISSUES			→		
OBESITY			→		
PSYCHOSOCIAL IMPACT			→		

Learn more about the common complications associated with each age group

*Foramen magnum stenosis is a result of impaired bone growth at the base of the skull that can cause cervicomedullary compression (CMC), which can lead to complications such as sleep-disordered breathing.

References: 1. Pauli RM. Achondroplasia: a comprehensive clinical review. *Orphanet J Rare Dis.* 2019;14(1):1. 2. Hoover-Fong J, Scott CI, Jones MC; Committee on Genetics. Health supervision for people with achondroplasia. *Paediatrics.* 2020;145(6):e20201010.








ACHONDROPLASIA COMPLICATIONS BY AGE GROUP

Infants



Knowing what to look for is key to proactive management, which may help mitigate complications and set proper expectations. Complications in infants may require specialized medical management, so it may be important that pediatricians partner with a physician with expertise in skeletal dysplasia, and provide referrals to the necessary specialists.¹

Adapted from “Health Supervision for People With Achondroplasia” published by the American Academy of Pediatrics. These are potential complications—individual experience will vary. For diagnosis and management, please follow clinical judgement.

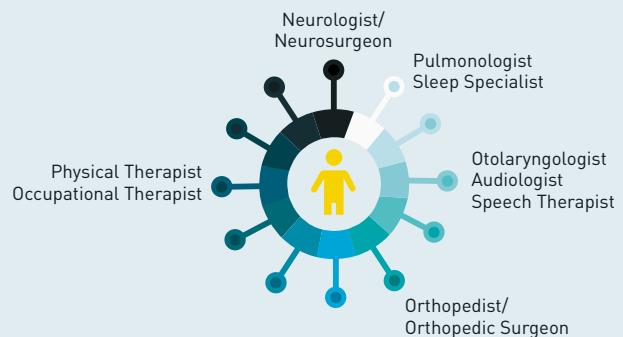
Potential Complication	Proactive Monitoring	Referral Specialist
 Cervicomedullary compression (CMC) ²	Cranial imaging if CMC is suggested in history, neurologic exam, and/or sleep study ²	Neurologist/Pediatric Neurosurgeon ²
 Sleep-disordered breathing ¹	Polysomnography ¹	Neurologist/Pediatric Neurosurgeon ¹ , Pediatric Pulmonologist ¹ , Sleep Specialist ¹
 Central sleep apnea ³	Polysomnography ^{1,2}	Neurologist/Pediatric Neurosurgeon ² , Pediatric Pulmonologist ^{1,2} , Sleep Specialist ¹
 Hydrocephalus ¹	Monitor with achondroplasia-specific occipital-frontal circumference (OFC) charts ^{1,2}	Neurologist/Pediatric Neurosurgeon ¹
 Hypotonia ¹	Assess for “floppiness,” weakness, sustained lower extremity clonus, asymmetric reflexes, or choking or gagging with eating ¹	Neurologist/Pediatric Neurosurgeon ¹ , Physical Therapist ³
 Otitis media (OM) ¹	Annual hearing assessment ¹ Recurrent OM may require assessment for surgical drainage ³	Otolaryngologist ² , Audiologist ¹ , Speech Therapist ¹
 Kyphosis ¹	Monitor for developmental delays in motor skill acquisition (compared with other children with achondroplasia) if persistent after walking. Counsel against unsupported sitting and devices that cause curved sitting ¹	Pediatric Orthopedist ¹ , Physical Therapist ³ , Occupational Therapist ³

2% to 7.5%

Risk of sudden death due to CMC at the foramen magnum⁴⁻⁶



<10% of children may require **surgical enlargement of foramen magnum**⁷



References: 1. Hoover-Fong J, Scott CI, Jones MC; Committee on Genetics. Health supervision for people with achondroplasia. *Pediatrics*. 2020;145(6):e20201010. 2. Wright MJ, Irving MD. Clinical management of achondroplasia. *Arch Dis Child*. 2012;97(2):129-134. 3. Ireland PJ, Pacey V, Zankl A, Edwards P, Johnston LM, Savarirayan R. Optimal management of complications associated with achondroplasia. *Appl Clin Genet*. 2014;7:117-125. 4. Ednick M, Tinkle BT, Phromchairak J, Egelhoff J, Amin R, Simakajornboon N. Sleep-related respiratory abnormalities and arousal pattern in achondroplasia during early infancy. *J Pediatr*. 2009;155(4):510-515. 5. Pauli RM. Achondroplasia: a comprehensive clinical review. *Orphanet J Rare Dis*. 2019;14(1):1. 6. Hecht JT, Francomano CA, Horton WA, Annegers JF. Mortality in achondroplasia. *Am J Hum Genet*. 1987;41(3):454-464. 7. Matsushita T, Wilcox WR, Chan YY, et al. FGFR3 promotes synchondrosis closure and fusion of ossification centers through the MAPK pathway. *Hum Mol Genet*. 2009;18(2):227-240.

ACHONDROPLASIA COMPLICATIONS BY AGE GROUP



Toddlers

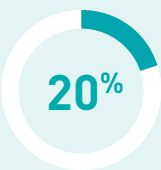As toddlers begin to speak and stand, additional complications may become more apparent. Knowing what to look for is key to proactive management, which may help mitigate complications and set proper expectations.

Adapted from “Health Supervision for People With Achondroplasia” published by the American Academy of Pediatrics. These are potential complications—individual experience will vary. For diagnosis and management, please follow clinical judgement.

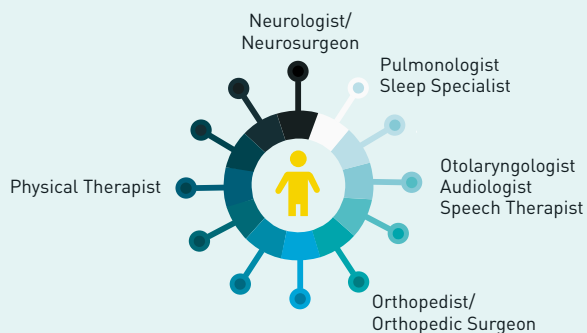
Potential Complication	Proactive Monitoring	Referral Specialist
Cervicomedullary compression (CMC) ¹	Cranial imaging if CMC is suggested in history, neurologic exam, and/or sleep study ¹	Neurologist/Pediatric Neurosurgeon ¹
Central sleep apnea ¹	Repeat polysomnography if worsening snoring, abnormal daytime tiredness, or slow developmental progress ^{1,2}	Neurologist/Pediatric Neurosurgeon ¹ , Pediatric Pulmonologist ^{1,2}
Sleep-disordered breathing ² Upper airway obstruction ¹	Repeat polysomnography if worsening snoring, abnormal daytime tiredness, or slow developmental progress ^{1,2}	Pediatric Otorhinolaryngologic Surgeon ¹ , Pediatric Pulmonologist ² , Sleep Specialist ²
Otitis media (OM) Hearing impairments ²	Annual hearing assessment ² Recurrent OM may require assessment for surgical drainage ³	Otolaryngologist ² , Audiologist ² , Speech Therapist ²
Speech difficulties ²	Perform a speech evaluation at no later than 2 years of age ²	Speech Therapist ²
Kyphosis ²	Monitor for shift from kyphosis to hyperlordosis with walking ¹	Pediatric Orthopedist ¹ , Physical Therapist ³
Genu varum ²	Perform physical examination ²	Pediatric Orthopedist ¹

2.5% risk

While the risk of **sudden death** decreases compared with infancy, it is still a significant concern (2.5% risk between the ages of 1 to 4 years)⁴



OM may contribute to speech delays. Concerns of **delayed speech** have been reported in ~20% of children with achondroplasia¹



References: 1. Wright MJ, Irving MD. Clinical management of achondroplasia. *Arch Dis Child*. 2012;97(2):129-134. 2. Hoover-Fong J, Scott CI, Jones MC; Committee on Genetics. Health supervision for people with achondroplasia. *Pediatrics*. 2020;145(6):e20201010. 3. Ireland PJ, Pacey V, Zank LA, Edwards P, Johnston LM, Savarirayan R. Optimal management of complications associated with achondroplasia. *Appl Clin Genet*. 2014;7:117-125. Published online June 24, 2014. 4. Hecht JT, Francomano CA, Horton WA, Annegers JF. Mortality in achondroplasia. *Am J Hum Genet*. 1987;41(3):454-464.









ACHONDROPLASIA COMPLICATIONS BY AGE GROUP



Children

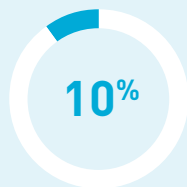Throughout childhood, it's important to keep an eye out for otolaryngologic, respiratory, and orthopedic issues as they can delay developmental milestones, such as speech and mobility, if left untreated.

Adapted from "Health Supervision for People With Achondroplasia" published by the American Academy of Pediatrics. These are potential complications—individual experience will vary. For diagnosis and management, please follow clinical judgement.

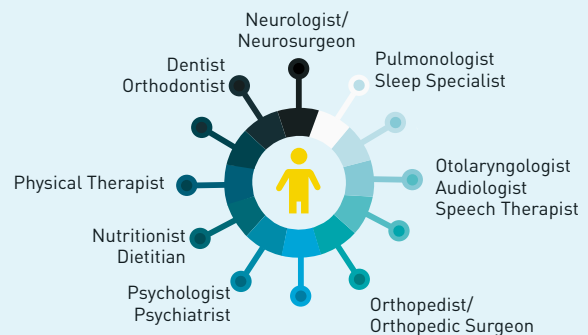
Potential Complication	Proactive Monitoring	Referral Specialist
 Obstructive sleep apnea ¹	Monitor for increased snoring, recurrent nighttime awakening. Polysomnography if obstructive sleep apnea is suspected ¹	Pediatric Pulmonologist ¹ , Sleep Specialist ¹
 Hearing impairments ²	Annual hearing assessment. Recurrent otitis media and subsequent hearing loss are the main cause of delayed verbal comprehension ^{1,2}	Otolaryngologist ¹ , Audiologist ¹ , Speech Therapist ¹
 Orthodontic issues ¹	Evaluate for malocclusion, crowded teeth, narrow upper jaw, and crossbite ³	Dentist ³ , Orthodontist ³
 Lumbar spinal stenosis (10 to 14 years) ²	Check deep tendon reflexes yearly for asymmetry or increased reflexes ¹	Neurologist/Pediatric Neurosurgeon ² , Pediatric Orthopedist ¹
 Lumbar hyperlordosis ¹	Assess for hip flexion contractures ¹	Physical Therapist or Pediatric Orthopedist ¹
 Genu varum ¹	Assess every 1 to 2 years or sooner if problems occur ¹	Pediatric Orthopedist ¹
 Obesity ¹	Monitor weight ¹	Nutritionist ^{1,2} , Dietitian ^{1,2}
 Psychosocial impact ²	Check on social adaptation ¹	Psychologist ⁴ , Psychiatrist ⁴

20% to 54%

Obstructive sleep apnea (OSA) is the most common respiratory disorder in children with achondroplasia^{5,6}



10% of children with achondroplasia are found to have **excessive weight gain**, suggesting that obesity starts in childhood⁷



References: 1. Hoover-Fong J, Scott CI, Jones MC; Committee on Genetics. Health supervision for people with achondroplasia. *Pediatrics*. 2020;145(6):e20201010. 2. Wright MJ, Irving MD. Clinical management of achondroplasia. *Arch Dis Child*. 2012;97(2):129-134. 3. Hunter AG, Bankier A, Rogers JG, Sillence D, Scott CI Jr. Medical complications of achondroplasia: a multicentre patient review. *J Med Genet*. 1998;35(9):705-712. 4. Unger S, Bonafé L, Gouze E. Current care and investigational therapies in achondroplasia. *Curr Osteoporos Rep*. 2017;15(2):53-60. 5. Onodera K, Sakata H, Niikuni N, Nonaka T, Kobayashi K, Nakajima I. Survey of the present status of sleep-disordered breathing in children with achondroplasia Part I. A questionnaire survey. *Int J Pediatr Otorhinolaryngol*. 2005;69(4):457-461. 6. Afsharpaiman S, Sillence DO, Sheikhatan M, Ault JE, Waters K. Respiratory events and obstructive sleep apnea in children with achondroplasia: investigation and treatment outcomes. *Sleep Breath*. 2011;15(4):755-761. 7. Hecht JT, Hood OJ, Schwartz RJ, Hennessey JC, Bernhardt BA, Horton WA. Obesity in achondroplasia. *Am J Med Genet*. 1988;31(3):597-602.





ACHONDROPLASIA COMPLICATIONS BY AGE GROUP



Teenagers

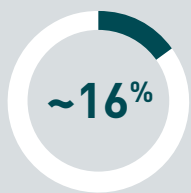While certain medical complications may persist into the teenage years, the psychosocial and functional implications of living with achondroplasia may become more pronounced. Knowing what to look for is key to proactive management.

Adapted from “Health Supervision for People With Achondroplasia” published by the American Academy of Pediatrics. These are potential complications—individual experience will vary. For diagnosis and management, please follow clinical judgement.

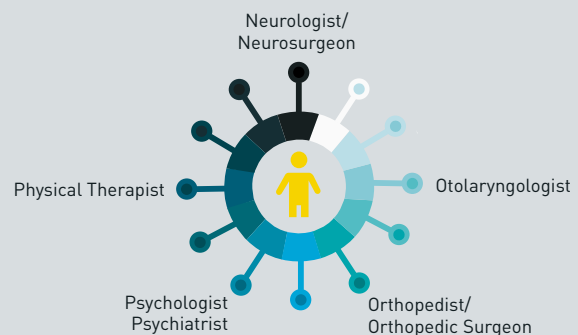
Potential Complication	Proactive Monitoring	Referral Specialist
 Hearing impairments ¹	Annual hearing assessment ²	Otolaryngologist ^{1,2}
 Spinal stenosis ¹	Complete a general and neurologically oriented physical examination. Monitor for any signs or symptoms of nerve compression and check deep tendon reflexes, tone, and sensory findings ²	Neurologist/Neurosurgeon ¹
 Chronic pain ²	Evaluate for pain and its effects on daily life and physical activity ²	Orthopedic Surgeon ³ , Physical Therapist ³
 Psychosocial impact ¹	Check in on social adaptation ²	Psychologist ⁴ , Psychiatrist ⁴

32%

of patients in one study experienced onset of **symptomatic spinal stenosis** by 18 years of age⁵



~16% of individuals between ages 10 and 20 **develop back pain**⁶



References: 1. Wright MJ, Irving MD. Clinical management of achondroplasia. *Arch Dis Child*. 2012;97[2]:129-134. 2. Hoover-Fong J, Scott CI, Jones MC; Committee on Genetics. Health supervision for people with achondroplasia. *Pediatrics*. 2020;145[6]:e20201010. 3. Ain MC, Abdullah MA, Ting BL, et al. Progression of low back and lower extremity pain in a cohort of patients with achondroplasia. *J Neurosurg Spine*. 2010;13[3]:335-340. 4. Unger S, Bonafé L, Gouze E. Current care and investigational therapies in achondroplasia. *Curr Osteoporos Rep*. 2017;15[2]:53-60. 5. Fredwall SO, Steen U, de Vries O, et al. High prevalence of symptomatic spinal stenosis in Norwegian adults with achondroplasia: a population-based study. *Orphanet J Rare Dis*. 2020;15[1]:123. 6. Hunter AG, Bankier A, Rogers JG, Sillence D, Scott CI Jr. Medical complications of achondroplasia: a multicentre patient review. *J Med Genet*. 1998;35[9]:705-712.







ACHONDROPLASIA COMPLICATIONS BY AGE GROUP



Adults

As a person with achondroplasia reaches adulthood, some medical conditions may resolve but many may progress, developing into more serious and potentially life-threatening complications. Pain and dietary management, as well as special considerations for obstetric and gynecologic care for women, may be necessary.

Adapted from “Health Supervision for People With Achondroplasia” published by the American Academy of Pediatrics. These are potential complications—individual experience will vary. For diagnosis and management, please follow clinical judgement.

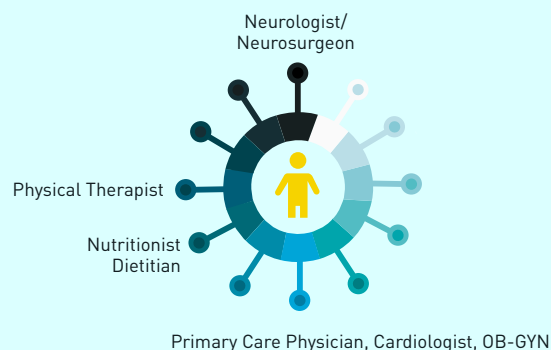
Potential Complication	Proactive Monitoring	Referral Specialist
 Spinal stenosis ¹	Evaluate for claudication, bladder dysfunction, leg and lower back pain, and leg weakness ¹	Neurologist/Neurosurgeon ²
 Chronic pain ²	Evaluate for pain and its effects on daily life and physical activity ²	Physical Therapist ¹
 Osteoporosis ^{3,4}	Carefully monitor bone mineral density (BMD) and examine osteoporosis-related symptoms ³	Primary Care Physician, Physical Therapist
 Obesity ²	Monitor weight ²	Nutritionist ⁵ , Dietitian ⁵
 Cardiovascular complications Hypertension ⁶	Monitor weight. Measure blood pressure as part of routine medical care and use forearm for blood pressure quantification if necessary ⁶	Cardiologist
 Obstetric and gynecological care ²	Monitor for uterine leiomyoma after the fifth decade of life ⁷	OB-GYN ²

40% to 70%

may experience **chronic back pain**⁴

20% to 30%

may have **spinal stenosis**.⁴ Additionally, **genu varum** can cause joint stress and pain in knees and ankles^{2,8}



References: 1. Ain MC, Abdullah MA, Ting BL, et al. Progression of low back and lower extremity pain in a cohort of patients with achondroplasia. *J Neurosurg Spine*. 2010;13(3):335-340. 2. Hoover-Fong J, Scott CI, Jones MC; Committee on Genetics. Health supervision for people with achondroplasia. *Pediatrics*. 2020;145(6):e20201010. 3. Taşoğlu Ö, Sahin Onat Ş, Yenigün D, Doğan Aslan M, Nakipoğlu GF, Özgürin N. Low bone density in achondroplasia. *Clin Rheumatol*. 2014;33(5):733-735. 4. Fredwall SO, Maanum G, Johansen H, Snekkevik H, Savarirayan R, Lidal IB. Current knowledge of medical complications in adults with achondroplasia: a scoping review. *Clin Genet*. 2020;97(1):179-197. 5. Hecht JT, Hood OJ, Schwartz RJ, Hennessey JC, Bernhardt BA, Horton WA. Obesity in achondroplasia. *Am J Med Genet*. 1988;31(3):597-602. 6. Pauli RM. Achondroplasia: a comprehensive clinical review. *Orphanet J Rare Dis*. 2019;14(1):1. 7. Allanson JE, Hall JG. Obstetric and gynecologic problems in women with chondrodystrophies. *Obstet Gynecol*. 1986;67(1):74-78. 8. Bacino CA. Achondroplasia. UpToDate website. <https://www.uptodate.com/contents/achondroplasia>. Updated December 15, 2020. Accessed February 9, 2021.